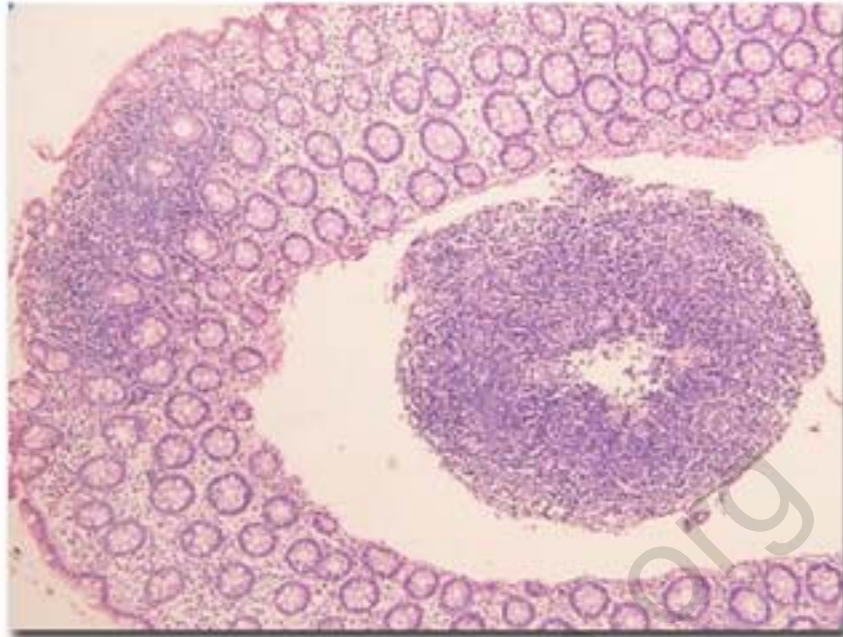


Clinical Quiz #22

An infant presents with bleeding per-rectum. Flexible sigmoidoscopy and biopsy are shown below:



What is your diagnosis ?

[Click for answers](#)

Contributed by [ÉŋÒ°Ñ¹ÉØøÀÒ¼à'çĴÁÈÒÃÒ³Ô¹Õ](#)

Pthaiga.com © 2019

Clinical Quiz # 22

Diagnosis: Colonic lymphonodular hyperplasia. The precise etiology has not been known. However, a link of cow milk allergy has been postulated. Treatment with protein hydrolysate formula and a low dose prednisolone are effective.

Pthaigastro.org